Check for updates

Article

AMERICAN ORTHOPAEDIC FOOT & ANKLE SOCIETY

Foot & Ankle International®
2019, Vol. 40(3) 318–322
© The Author(s) 2018
Article reuse guidelines:
sagepub.com/journals-permissions
DOI: 10.1177/1071100718809357
journals.sagepub.com/home/fai

Radiographic Analysis of National Football League Players' Fifth Metatarsal Morphology Relationship to Proximal Fifth Metatarsal Fracture Risk

Sydney C. Karnovsky, BA[1], Andrew J. Rosenbaum, MD[2], Bridget DeSandis, BA[1], Christopher Johnson, MD[3], Conor I. Murphy, MD[4], Russell F. Warren, MD[1], Samuel A. Taylor, MD[1], and Mark C. Drakos, MD[1]

Abstract

Background: Fractures of the proximal fifth metatarsal are one of the most common foot injuries in athletes. Repetitive stresses endured by the fifth metatarsal can lead to stress fracture, delayed union, and refracture, making optimal treatment challenging. A radiographic analysis of fifth metatarsal morphology and foot type in National Football League (NFL) players was performed to investigate morphologic risk factors for these injuries.

Methods: This was a case-control study that looked at NFL players treated between 1992 and 2012, as well as participants at the NFL Combine. Ninety-six feet (51 athletes) were included. Fractures were present in 15 feet. Two reviewers assessed fifth metatarsal morphology and foot type on anteroposterior, lateral, and oblique radiographs. Differences in foot type and metatarsal morphology between athletes with and without fractures were determined.

Results: On anteroposterior radiographs, significant differences in apex medullary canal width, 4-5 intermetatarsal angle, fifth metatarsal angle, and talar head uncovering were observed between fractured and non-fractured feet ($P = .001$, .003, .004, .008, respectively). On lateral radiographs, significant differences in the fifth metatarsal length, distance to apex, apex height, fifth metatarsal angle, and talocalcaneal angle were observed between fractured and nonfractured feet ($P = .04$, .01, .02, .01, .01, respectively). On oblique radiographs, a significant difference was observed in apex height between fractured and nonfractured feet ($P = .002$).

Conclusion: Individuals with long, narrow, and straight fifth metatarsals with an adducted forefoot were most at risk for fifth metatarsal fractures. With this insight, attempts at fracture prevention can be implemented via footwear modifications, orthoses, and off-loading braces that account for those aforementioned morphologic attributes that place athletes at risk.

Level of Evidence: Level III, retrospective comparative study.

Keywords: fifth metatarsal morphology, metatarsus adductus, Jones fracture, NFL

Jones fractures, which were first described in 1902 by Sir Robert Jones, occur at the proximal fifth metatarsal (MT) metaphysis, 1.5 to 3 cm distal to the tuberosity.[11] The fifth MT acts as a fulcrum for the strong ligamentous and capsular attachments that occur between the fourth and fifth MT and the fifth MT and the cuboid, putting it at higher risk for injury.[7,18] The proximal diaphyseal area is a watershed area, meaning there is a low blood supply.[3,7] Because of the decreased blood supply and high demands of the area, Jones fractures are often difficult to treat and are at an increased risk for developing either a delayed union or nonunion.[14]

Operative treatment is indicated in the majority of Jones fractures, particularly in younger, active populations.[5]

[1]Hospital for Special Surgery, New York, NY, USA
[2]Albany Medical College, Albany, NY, USA
[3]SUNY-Upstate Medical Center, Syracuse, NY, USA
[4]Department of Orthopaedic Surgery, University of Pittsburgh, Pittsburgh, PA, USA

Corresponding Author:
Sydney C. Karnovsky, BA, Hospital for Special Surgery, 535 East 70th Street, New York, NY 10021, USA.
Email: s.karnovsky@gmail.com

Table 1. Radiographic Parameters.

AP	Lateral	Oblique
MT length	MT length	Apex height
Distance to apex	Distance to apex	Fifth MT angle
Distance to fracture	Apex medullary canal width	
Apex medullary canal width	Apex height	
Apex height	Fifth metatarsal angle	
Fourth-fifth intermetatarsal angle	Meary angle	
Fifth metatarsal angle	Calcaneal pitch	
Meary angle	Talocalcaneal angle	
Talar head uncovering		

Abbreviations: AP, anteroposterior; MT, metatarsal.

Conservative treatment, which is typically non-weightbearing for varied durations in a cast, is usually reserved for older patients with lower demands, patients with medical comorbidities rendering surgery unsafe, and patients who have limited physical demands and can remain non-weightbearing for a period to lower the risk of nonunion.[15] Downsides of conservative treatment include increased time to union, as well as high rates of nonunion and refracture.[9] Operative treatment is varied, and current options include autogenous inlay bone graft, solid and cannulated screw systems, plates, and tension band constructs.[8] However, even with operative treatment, prevelance of refracture is high, with reports ranging from 4% to 12% of athletes.[11,16]

High rates of refracture and delayed healing in Jones fractures are problematic because these fractures are seen predominantly in athletes and can cause athletes to miss extended amounts of playing time, with an average rate of 13.6 missed weeks in soccer[3] and 8 to 10 weeks to an entire season in football.[8,9,11] In the NFL, Jones fractures have been reported to account for 17.8% of all foot fractures, which is significantly larger than the 0.7% to 1.9% reported in the general population and, unfortunately, refracture occurs at a surprisingly high rate.[1,17] It is important to isolate factors that put players most at risk to develop a Jones fracture in order to take measures to protect players and maximize playing time as well as to understand risk for refracture. Furthermore, it is helpful to identify if the stresses causing the injury are mechanical, biological, or both.

Several studies cite different morphologic factors that may lead to an increased risk of Jones fracture, and we believe that it is important to further this work. If morphologic factors can be isolated, this could allow for proactive action to be taken in order to prevent fracture as well as to help teams identify which players are at an increased risk of refracture to guide healing and treatment in injured players.

To date, several studies have looked at whether foot morphology plays a role in predicting who is at an increased risk for developing a Jones fracture. Though these studies are limited, there is some consensus that seems to point to forefoot adductus as a leading risk factor.[6,16] However, other studies have reported no significant morphologic predictors.[7] In the current study, we aimed to look at a group of elite football players and NFL prospects in order to assess fifth MT morphology and foot type on anteroposterior (AP), lateral, and oblique radiographs to determine if there are any clear morphologic risk factors for fifth MT fractures.

Methods

This was a case-control study that evaluated a total of 96 feet from 51 athletes. Potential study participants included NFL players with zone 2 fifth MT fractures treated by the senior authors between 1992 and 2012 as well as participants in the NFL Combine with foot radiographs. Proximal fifth MT fractures were present in 15 of the feet. All fractures were zone 2 fifth MT fractures. A convenience sample was used to establish a cohort of NFL players with zone 2 fifth MT fractures treated by the senior authors as well as participants in the 2014 NFL Combine with foot radiographs.

Two of the reviewers who were both orthopedic foot and ankle fellows then independently assessed fifth MT morphology and foot type on anteroposterior (AP), lateral, and oblique radiographs according to the specific parameters listed in Table 1. AP radiograph measurements are shown in Figure 1 and lateral radiograph measurements are shown in Figure 2.

The reviewers' measurements for each parameter were averaged for each foot. Differences in foot type and metatarsal morphology between athletes with and without fractures were determined via Student *t* test analysis. The Statistical Package for the Social Sciences (SPSS; IBM, Armonk, NY) was used. A P value of $<.05$ was used to determine statistical significance.

Results

Demographic data were recorded for players at the NFL combine (Table 2), and reviewers' interobserver reliability was found to be good to very good for radiographic

Figure 1. Anteroposterior radiograph measurements. (A) fourth-fifth intermetatarsal angle, (B) fifth metatarsal angle.

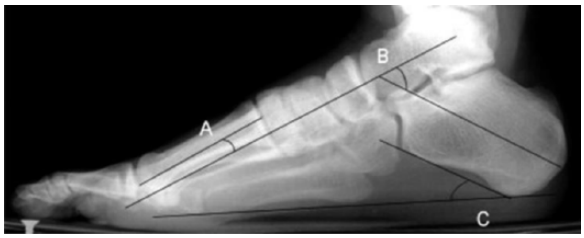

Figure 2. Lateral radiograph measurements. (A) Meary angle, (B) talocalcaneal angle, (C) calcaneal pitch.

Table 2. Average Demographic Information Recorded for Players at the NFL Combine.

Player Demographic Information	Mean	Range
Age, y	22.4	21.0-26.0
Height, feet (′) inches (″)	6′2″	5′8″-6′8″
Weight, lb	251	183-336

measurements based on 2-way fully crossed analysis of variance design.

On AP radiographs, 9 different measurements were performed, with statistically significant differences between the fractured and non-fractured feet in 4 of the 9 measurements tested (Table 3). In the fractured feet, the apex medullary canal width was significantly (P = .001) less than nonfractured feet, with the mean width being 4.7 mm compared to 5.5 mm in the nonfractured feet. The fourth-fifth intermetatarsal angle was significantly less (P = .003) in the fractured feet as well, with a mean of 6.3 degrees compared to 7.9 degrees in the nonfractured feet. Talar head uncovering was also significantly (P = .008) less in the fractured feet (mean 18) than in the nonfractured feet (mean 22.7). The fifth MT angle was significantly (P = .004) greater in the fractured feet (mean 3.9 degrees) compared to the nonfractured feet (mean 2.6 degrees).

On lateral radiographs, statistically significant differences between the fractured and nonfractured group were found in 5 of the 8 measurements tested (Table 3). Fifth MT length was determined to be significantly (P = .040) greater in the fractured feet (mean 90.0 mm) than in the nonfractured feet (mean 86.1 mm). Distance to the apex was also significantly (P = .010) greater in the fractured feet (mean 53.6) than in the nonfractured feet (mean 50.1). Apex height, fifth MT angle, and talocalcaneal angle were all significantly (P = .020, P = .010, P = .010; respectively) less in the fractured feet than the nonfractured feet with means of 4.6 mm, 6.2 degrees, and 39.0 degrees, respectively, in the fractured feet and means of 5.3 mm, 8.0 degrees, and 41.8 degrees, respectively, in the nonfractured feet.

On oblique radiographs, a significant (P = .002) difference was observed in apex height with a smaller mean height in fractured feet (mean 4.5 mm) as compared to nonfractured feet (mean 5.5 mm). The fractured feet were found to be longer, straighter, and narrower than the nonfractured feet. Feet showing metatarsus adductus radiographically were more likely to be fractured than nonfractured.

Discussion

Past biomechanical studies have focused on Jones fractures, attempting to assess whether or not foot type and direction of force affects the incidence of Jones fractures. One of the first biomechanical studies showed that Jones fractures are not caused by inversion injuries as previously hypothesized.[10] This early study proposed that a vertical force, a mediolateral force, or a combination of the two act on the base of the fifth MT with a posterior ground force that then brings patients onto their metatarsal heads and concentrates the vertical and mediolateral forces on the lateral metatarsal.[10] A later study also agreed that inversion injuries typically are not the cause of Jones fractures.[18] While these early studies looked at force in order to begin to better understand Jones fractures, they did not attempt to describe if any specifc foot type put patients at an increased risk of experiencing these forces. We aimed to address that question in the current study.

Though a number of studies have looked at whether foot type/morpholgoy affects risk of Jones fracture, all reports have varied size cohorts of feet and many find conflicting

Table 3. Averaged Radiographic Findings.

	Fractured (n = 15)		Nonfractured (n = 81)		
	Mean	SD	Mean	SD	*P* Value
Anteroposterior view					
Metatarsal length	92.1	6.9	90.7	6.9	.344
Distance to apex	56.2	11.7	26.2	55.4	.733
Distance to fracture	28.3	5.2	26.2	5.7	.581
Apex medullary canal width	4.7	0.8	5.5	2.5	.001*
Apex height	4.0	1.3	4.5	5.6	.310
Fourth-fifth intermetatarsal angle	6.3	2.6	7.9	2.4	.003*
Fifth metatarsal angle	3.9	1.9	2.6	2.7	.004*
Meary angle	8.5	5.2	9.2	6.7	.664
Talar head uncovering	18.0	9.4	22.7	7.6	.008*
Lateral view					
Metatarsal length	90.0	6.7	86.1	8.8	.040*
Distance to apex	53.6	6.0	50.1	5.6	.010*
Apex medullary canal width	5.8	1.1	5.9	1.4	.680
Apex height	4.6	1.5	5.3	1.4	.020*
Fifth metatarsal angle	6.2	2.8	8.0	3.2	.010*
Meary angle	−2.8	7.1	−3.7	13.2	.600
Calcaneal pitch	14.4	4.4	16.6	5.3	.070
Talocalcaneal angle	39.0	4.5	41.8	6.5	.010*
Oblique view					
Apex height	4.5	1.7	5.5	1.5	.002*
Fifth metatarsal angle	6.8	3.7	7.7	4.0	.310

*P value $<.05$.

results. Studies have also often combined zone 2 and zone 3 fractures during analysis because of prior reccomendation that there is no need to distinguish between these fracture types in terms of treatment.[2] One study investigated whether patients with cavovarus alignment were more likely to have Jones fractures and, despite previous inclination that a high arch was a risk factor, they found no signifincat differences in bilateral arches between injured and matched noninjured soccer players.[7] Furthermore, they found no evidence to support specific foot type having a relation to the occurence of Jones fractures.[7] In contrast, another study looked at 75 patients with Jones fractures and measured the degree of plantar gap (distance between the fracture margins on the plantar lateral side of the fifth MT bone in an oblique radiograph) in all patients.[13] They found that there was a strong correlation between time to union and plantar gap.[13] In a different study conducted by the same investigator, they concluded that both cavus feet and curved (as opposed to straight) bones were found to have an increased association with Jones fractures.[12] Finally, another study examined the morphology of the fifth MT on CT, specifically with respect to the implications of its unique morphology on selecting an appropriately sized screw for surgical repair in order to prevent malunion and refracture.[4] This study determined that lateral radiographs were best for estimating screw length and also showed a significant relationship between patients' size and the curvature of the fifth MT.[4] As height, weight, and BMI increased, the bowing of the fifth MT similarly increased, implicating a relationship between physical characteristics, foot morphology, and fifth MT fractures.[4]

In a similar study, the NFL combine database for a single team was reviewed to identify players between 2004 and 2009, and 74 fractures were identified in 68 players.[1] Coronal plane alignment, as measured by talar first metatarsal angle, talar second metatarsal angle, and talar fifth MT angle, did show significant differences between the fracture and control groups, with an associated increased fracture occurrence in athletes with a varus foot alignment. Alignment in the sagittal plane, as measured by Meary angle and the calcaneal pitch, did not differ between the fracture and control groups.[1] Our results found that athletes with an adducted forefoot, long, narrow, and straight fifth MTs, and those with a hindfoot valgus were at elevated risk for developing a Jones fracture. This conclusion contradicts that found by previous studies and suggests that further investigation is warranted. These findings are also more common in football and basketball players, possibly representing a selection bias.

Our finding that an adducted forefoot increased an athlete's risk of developing a Jones fracture has been recently reported by both O'Malley et al.[16] and Fleischer et al.[6] Specifically, O'Malley et al. looked at 10 NBA athletes and concluded that those most at risk for Jones fractures were those with high fourth to fifth intermetatarsal angles, high fifth MT lateral deviation, and well as high metatarsus adductus angles. Fleischer et al. looked at a series of 50 patients with Jones fractures with 200 matched controls and found that metatarsus adductus angle and the fourth-fifth intermetatarsal angle were the only significant variables of 13 that they looked at.[6] They concluded that metatarsus adductus led to a 2.4 times increased risk of Jones fracture.[6]

Limitations of our study include a small sample size, particularly with respect to the number of players identified with Jones fractures, as well as our study's nature as a retrospective analysis. Because retrospective data were obtained from the NFL Combine database, some of the data were incomplete.

Conclusion

Given these recent studies and our own work, we believe that the athletes most at risk for Jones fractures are those with metatarsus adductus. Whether or not the length and diameter of the fifth MT are at an increased risk still remains debated. Based on our results, we believe that athletes with long, straight, and narrow fifth MTs are also at an increased risk. Athletes at heightened risk for Jones fractures may be able to adopt footwear modifications, including possible orthoses and/or off-loading braces that will minimize these morphologic risk factors. Further study is warranted, looking at much larger patient populations as well as matched controls, in order to continue to isolate risk factors for Jones fractures.

Declaration of Conflicting Interests

The author(s) declared no potential conflicts of interest with respect to the research, authorship, and/or publication of this article. ICMJE forms for all authors are available online.

Funding

The author(s) received no financial support for the research, authorship, and/or publication of this article.

ORCID iD

Conor I. Murphy, MD, https://orcid.org/0000-0003-3297-6983

References

1. Carreira DS, Sandilands SM. Radiographic factors and effect of fifth metatarsal Jones and diaphyseal stress fractures on participation in the NFL. *Foot Ankle Int*. 2013;34(4):518-522.
2. Chuckpaiwong B, Queen RM, Easley ME, Nunley JA. Distinguishing Jones and proximal diaphyseal fractures of the fifth metatarsal. *Clin Orthop Relat Res*. 2008;466(8):1966-1970.
3. Den Hartog BD. Fracture of the proximal fifth metatarsal. *J Am Acad Orthop Surg*. 2009;17(7):458-464.
4. DeSandis B, Murphy C, Rosenbaum A, et al. Multiplanar CT analysis of fifth metatarsal morphology. *Foot Ankle Int*. 2016;37(5):528-536.
5. Ekstrand J, Torstveit MK. Stress fractures in elite male football players. *Scand J Med Sci Sport*. 2012;22(3):341-346.
6. Fleischer AE, Stack R, Klein EE, Baker JR, Weil L, Weil LS. Forefoot adduction is a risk factor for Jones fracture. *J Foot Ankle Surg*. 2017:1-5.
7. Hetsroni I, Nyska M, Ben-Sira D, et al. Analysis of foot structure in athletes sustaining proximal fifth metatarsal stress fracture. *Foot Ankle Int*. 2010;31(3):203-211.
8. Hulko A, Orava S, Nikula P. Stress fractures of the fifth metatarsal in athletes. *Ann Chir Gynaecol*. 1985;74:233-238.
9. Hunt KJ, Anderson RB. Treatment of Jones fracture nonunions and refractures in the elite athlete. *Am J Sports Med*. 2011;39(9):1948-1954.
10. Kavanaugh JH, Brower TD, Mann R V. The Jones fracture revisited. *J Bone Jt Surg*. 1978;60A(6):776-782.
11. Lareau CR, Hsu AR, Anderson RB. Return to play in National Football League players after operative Jones fracture treatment. *Foot Ankle Int*. 2016;37(1):8-16.
12. Lee KT, Kim KC, Park YU, Kim TW, Lee YK. Radiographic evaluation of foot structure following fifth metatarsal stress fracture. *Foot Ankle Int*. 2011;32(8):796-801.
13. Lee KT, Park YU, Young KW, Kim JS, Kim JB. The plantar gap: Another prognostic factor for fifth metatarsal stress fracture. *Am J Sports Med*. 2011;39(10):2206-2211.
14. Low K, Noblin JD, Browne JE, Barnthouse CD, Scott AR. Jones fractures in the elite football player. *J Surg Orthop Adv*. 2004;13(3):156-160.
15. Mologne TS, Lundeen JM, Clapper MF, O'Brien TJ. Early screw fixation versus casting in the treatment of acute Jones fractures. *Am J Sports Med*. 2005;33(7):970-975.
16. O'Malley MJ, DeSandis B, Allen A, Levitsky M, O'Malley Q, Williams R. Operative treatment of fifth metatarsal Jones fractures (zones II and III) in the NBA. *Foot Ankle Int*. 2016;37(5):488-500.
17. Ochenjele G, Ho B, Switaj PJ, Fuchs D, Goyal N, Kadakia AR. Radiographic study of the fifth metatarsal for optimal intramedullary screw fixation of Jones fracture. *Foot Ankle Int*. 2015;36(3):293-301.
18. Wright RW, Fischer D, Shively R, Heidt RS, Nuber GW. Refracture of proximal fifth metatarsal (Jones) fracture after intramedullary screw fixation in athletes. *Am J Sports Med*. 2000;28(5):732-736.w